




Contents lists available at ScienceDirect

The Knee



The effect of femoral tunnel widening on one-year clinical outcome after anterior cruciate ligament reconstruction using Ziploop® technology for fixation in the cortical bone of the femur

Benjamin Basson *, Rémi Philpott, Thomas Neri, Jean François Meucci, Bertrand Boyer, Frédéric Farizon

Université Jean Monnet, CHU de St Etienne, Laboratoire de Physiologie de l'Exercice (LPE), Avenue Raimond, 42055 St Etienne Cedex 2, France

ARTICLE INFO

Article history:

Received 31 July 2014

Received in revised form 31 March 2015

Accepted 1 June 2015

Available online xxx

Keywords:

Anterior cruciate ligament

STG

Cortical fixation

Ziploop

Widening

ABSTRACT

Background: The effect of femoral tunnel widening on clinical results after anterior cruciate ligament (ACL) reconstruction has rarely been investigated. In our study, ACL reconstructions were performed using semitendinosus and gracilis (STG) tendon grafts and single cortical fixation on the femoral side. The aim was to analyse femoral tunnel widening at one year and evaluate the effect of femoral tunnel widening on clinical and laximetric outcome.

Methods: Forty-six patients were enrolled in this prospective continuous single operator monocenter study. Clinical protocol included preoperative and one-year evaluation with subjective and objective clinical scores of the International Knee Documentation Committee (IKDC). Computerized tomography (CT) scan was used for radiographic examination at one-year follow-up. The amount of femoral tunnel widening was measured by means of the 3D image processing OsiriX software. The cross-sectional area of each tunnel was measured at four different locations.

Results: The subjective IKDC score improved from a preoperative score of 50 to a one-year postoperative score of 81.8. The side-to-side difference in knee laxity evolved from 2.94 mm to 0.74 mm. The objective IKDC score at last follow-up was rated A in 27 patients and B in 17. CT scan data revealed a mean cone shape widening of the femoral tunnel of 49.32%. Femoral tunnel widening at the level of the joint (F4) was negatively correlated with the IKDC subjective score at one year.

Conclusion: This study revealed a significant widening of the femoral tunnel by demonstrating its conical shape at one postoperative year. A significant correlation could be established between femoral tunnel widening close to the joint and IKDC scores.

© 2015 Elsevier B.V. All rights reserved.

1. Introduction

During surgical anterior cruciate ligament (ACL) reconstruction, graft fixation aims at maintaining sufficient tension and resistance during the whole process of graft incorporation into bone. Numerous femoral fixation devices are available for ACL reconstruction using a semitendinosus and gracilis (STG) tendon graft. These fixation devices are classified according to bone density: cortical, cortico-spongious and intraspongious fixations. Intraspongious fixation devices such as interference screws have the lowest resistance [1,2]. The ZipLoop® pure cortical fixation device (Biomet, Valence, France) allowed for cortical

graft fixation using a constant tension despite its adjustable length. Therefore, the length of the femoral bone tunnel could fit each patient.

Femoral tunnel widening was reported with all types of femoral fixation devices. Widening occurred from the third postoperative month then stabilized around two years after surgery [3,4].

For many years, the widening of the fixation tunnels was not considered responsible for the quality of knee stabilization [4,7,10–12]. More recently, Zijl et al. [13] found a significant correlation between tibial tunnel widening and residual laxity after two postoperative years with a quadriceps tendon graft. Postoperative tunnel widening reported short and long term clinical consequences.

According to our hypothesis, graft fixation in the cortical bone of the femur using Ziploop technology is likely to affect residual knee laxity and mean term clinical outcome.

The purpose of this study was to evaluate the amount of femoral tunnel widening one year after ACL reconstruction using an STG tendon

* Corresponding author.

E-mail address: benjaminbasson@gmail.com (B. Basson).

graft and to determine the clinical and laximetric significance of any such tunnel enlargement.

2. Material and methods

2.1. Population

This prospective monocenter study was conducted in a University center.

Included were patients having undergone ACL reconstruction with an STG tendon graft and Ziploop® fixation. Clinical diagnosis of an ACL tear was made using the pivot shift and Lachman tests. Such diagnosis was confirmed with MRI.

Excluded were patients with contraindication to surgery or use of this fixation device, those taking corticosteroids exceeding 10 mg/day, patients receiving anti-inflammatory therapy or suffering from chronic inflammatory disease and female patients with on-going pregnancy.

Subjects had to provide free and informed consent during inclusion.

Preoperative examination included complete and standardized clinical assessment with IKDC subjective and objective scores as well as the Short Form 36 (SF36) health survey. A laximetry test (GNRB arthrometer) was also performed. This method was seen as preferable to the Telos one since it provided a better sensitivity and specificity [14].

At 12 postoperative months, the same standardized clinical exam was performed using CT scan to evaluate the degree of femoral tunnel widening. Despite its radiation dose, scan was preferred to 2D standard radiography which lacked accuracy as described by Fules et al. [15].

2.2. Surgical technique

Harvesting of the STG graft was performed at the beginning of the surgical procedure from the homolateral limb at the site of the ACL tear and using a tendon stripper.

The graft was passed through both loops of the ZipLoop® fixation device.

Tibial and femoral tunnels were created independently in an “inside-out” fashion. The drilling diameter of tibial and femoral tunnels matched the graft diameter. In this study, all grafts were nine millimeters in diameter.

The femoral tunnel was performed with the knee in hyper flexion, and oriented at the 10:00 position on a right knee or 2:00 position on a left knee.

A guide wire was used for optimal tunnel placement (upward and external). A nine millimeters diameter and 30 mm long femoral tunnel was made using a graduated pin. It was then extended to the lateral cortex of the femur with a 4.5 mm diameter tunnel. An eye pin with a ZipLoop® fixation at its distal end was passed through the femoral tunnel. The eye pin was then removed from the femur thus securing the Ziploop® device in the femoral cortex.

The graft was inserted through the tunnels until it abuts at the junction between nine millimeters and 4.5 mm diameters. At that precise moment, the ZipLoop® was pulled through the tibial tunnel for fixation in the femoral cortex.

The knee was cycled for ZipLoop® tensioning.

Tibial fixation was performed using an interference screw along with a ligament staple.

2.3. Scan and enumeration technique

Scan was performed using the Bright Speed GE® Elite 16 slice multi-detector scanner. It was combined with an automated dose reduction software. Standardized protocol included a spiral CT data acquisition, without intravenous injection of an iodinated contrast agent (80 kV, 50 mAs), providing 0.6 mm thick slices from the upper end of the femoral tunnel up to the inferior end of the tibial tunnel. Multiplanar

reconstructions were performed. The OsiriX® (The Osirix Foundation Geneva Switzerland) image processing software was selected.

Femoral tunnel widening at 12 postoperative months was evaluated by comparing the measured cross-sectional area (MA) with the initially drilled tunnel size (DTS) (nine millimeters diameter). The 3D reconstructions obtained by this software allowed 4 staged measurements of the femoral tunnel area perpendicular to the axis of the graft (Illustration no. 1) to be performed. These measurements were made along the femoral portion of the graft. For greater accuracy, we did not use the “best fit” circle method as described by Fules et al. [15]. The “point by point” technique as described by Robinson et al. [16] was considered more accurate and reproducible and provided a better outline of the bone tunnel periphery (ovoid). At least 13 points were connected to one another in order to determine the measured cross-sectional area (MA).

Tunnel widening was expressed as a percentage of increase in tunnel cross-sectional area: increase in area (IA) = $(MA - DTS) / DTS$ according to its position in the tunnel; that is from proximal to distal: IA1; IA2; IA3; IA4 (IA4 being two millimeters from the joint line, IA3 being 10 mm from the joint line, IA2 being 20 mm from the joint line and IA1 being 25 mm from the joint line). Based on these data, the tunnel area at F1; F2; F3; F4 (F4 being 2 mm from the joint line, F3 being 10 mm from the joint line, F2 being 20 mm from the joint line and F1 being 25 mm from the joint line) could be determined.

2.4. Statistical analysis

Statistical analysis was performed using the StatView software (SAS Institute, Cary, North Carolina). The Pearson correlation coefficient was used to characterize the relationship between femoral tunnel widening and quantitative clinical parameters.

A statistical comparison was carried out by using Student tests. The level of statistical significance was set at $p \leq 0.05$.

3. Results

3.1. Population

Our study included 46 patients (36 males and 10 females) with a mean age of 24 years [13–43 years], who underwent ACL reconstruction between January, 24th 2011 and December, 5th 2012. The mean follow-up period was 13 months [eight to 16 months]. There were 23 left and 23 right knees. No patient had early or last-term postoperative complication having required revision surgery.

3.2. Scan results (Fig. 1)

At one year, the typical appearance of the femoral tunnel widening was conical in shape with a mean increase in the tunnel area of $49.32\% \pm 0.52$; a 95% confidence interval of [41.36%–57.28%]. In F1, the mean tunnel area was $68.52 \text{ mm}^2 \pm 23.85$; a 95% confidence interval of [60.96–102.08] which is an increase of +7.72%. In F2, the mean tunnel area was $92.46 \text{ mm}^2 \pm 29.51$; a 95% confidence interval of [82.68–118.44] which is an increase of 45.47%. In F3, the mean tunnel area was $107.15 \text{ mm}^2 \pm 30.88$; a 95% confidence interval of [78.07–118.25] which is an increase of 68.58%. In F4, the mean tunnel area was $111.6 \text{ mm}^2 \pm 30.48$; a 95% confidence interval of [102.08–129.09] which is an increase of 75.5% ($p < 0.001$).

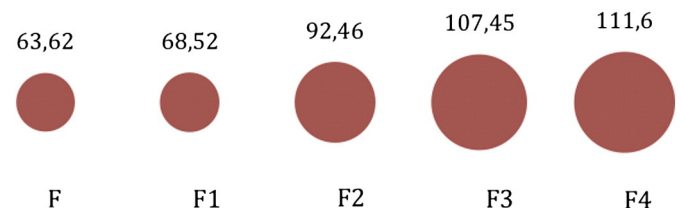


Fig. 1. Mean cross-sectional area of femoral tunnel at one year according to its location, in mm².

3.3. Clinical results (Table 1)

3.3.1. IKDC objective score

Preoperative IKDC objective score was rated B in two patients, C in 33 and D in 11. At one year, the IKDC objective score was A in 27 patients and B in 17. There was still one patient rated IKDC C and one rated IKDC D.

A significant relationship between femoral tunnel widening and objective IKDC score at F4 ($p = 0.043$) could be established: At last follow-up, the mean diameter for IKDC A at F4 was $103 \text{ mm}^2 \pm 27$; 126 mm^2 for IKDC B at F4 ± 30.77 ; 126 mm^2 for IKDC C at F4 and 128 mm^2 for IKDC D at F4.

3.3.2. IKDC subjective score

The mean preoperative IKDC subjective score was 50 ± 14.9 with a 95% confidence interval of [45.5–76.6]. At one postoperative year, this score was 81.8 ± 17.3 with a 95% confidence interval of [54.5–87].

Widening of the femoral tunnel in F4 could be correlated with the IKDC subjective score at one year. It was a reverse correlation with a -0.3 coefficient ($p = 0.05$)

3.3.3. SF 36 score

The SF 36 score improved from 70.94 ± 13.87 (SD); extreme values [41–95] preoperatively to 86.56 ± 9.33 (SD) extreme values [51–98] at one year ($p < 0.05$).

The SF 36 was not influenced by femoral tunnel widening ($p > 0.05$).

3.3.4. GNRB laximetry results

The preoperative side-to-side difference in knee laxity was 2.94 ± 2.38 mm (SD); 95% confidence interval [1.66–3.1]. At one year, the side-to-side difference in knee laxity was 0.74 ± 1.92 mm (SD); 95% confidence interval [1.33–2.5].

Laximetry was not affected by femoral tunnel widening ($p > 0.05$).

3.4. Complications

There was no iterative rupture at last follow-up. Two patients reported unsatisfactory clinical results. Radiographic findings did not demonstrate any tunnel malposition and scan analysis did not show a greater tunnel widening compared with other subjects.

4. Discussion

This study has demonstrated a significant difference in femoral tunnel widening which could be correlated to the changes in functional scores. There was a significant correlation between the subjective and objective IKDC scores and femoral tunnel widening close to the joint line at one postoperative year. This correlation was low and negative. Such radio-clinical relationship has never been reported in the literature.

However, our study has certain limitations.

The population of patients was nonhomogeneous in terms of gender (36 males and 10 females) and age (13 years and 43 years). Indeed, the hormonal influence and quality of cancellous bone are two factors likely to affect significantly the osseointegration process.

In order to reduce the measurement biases, a minimum of 13 points were placed on the femoral tunnel periphery. By using the point by point technique described by Robinson et al. [16], the Osirix® software could accurately determine the cross-sectional area. However, the operator dependence of this method can be criticized. Nevertheless, this technique appeared as reproducible due to the standardized measurements (two millimeters; 10 mm; 20 mm and 25 mm). Moreover, it was established by Fules et al. [15] that 2D radiographic analysis significantly underestimated the degree of tunnel widening. According to his study, a 10% widening corresponded to a 21% widening due to the linear rather than logarithmic mathematical relationship. Our measurement method for femoral tunnel widening demonstrated a

greater accuracy than the face and lateral radiographic technique. Our 3D reconstruction using the Osirix® software allowed a reproducible measurement of tunnel widening which was not circumferential but eccentric.

According to our findings, the mean femoral tunnel widening was 49.32% at one year. These results correlate those reported in a literature review (Table 2) demonstrating femoral tunnel widenings ranging from 30% to 50%. Plaweski et al. [17] reported a mean increase in femoral tunnel diameter of 58% at four years compared with the initially drilled tunnel size and using Endobutton CL® (Smith et Nephew) fixation. Silva et al. [5] also reported a 30% widening of the posterolateral tunnel and a 34% widening of the anteromedial tunnel at three postoperative months using a double-bundle STG graft and Endobutton CL® fixation.

However, the time to occurrence of tunnel widening varies according to authors. Widening occurred within the first three months according to Silva et al. [5] and during the first postoperative year according to Peyrache et al. [4]. All authors agreed on the multifactorial origin of tunnel widening combining:

- Biological factors: first related to an immune response causing reabsorption of the interference screw and secondly to an osteonecrosis secondary to hyperthermia after tunnel drilling [5].
- Biomechanical factors: related to micromotion of the graft tissue inside the tunnel: longitudinal graft excursion in the bone tunnel (Bungee effect) and transverse motion of tendon in the tunnel (windshield-wiper effect) [6–8]. The longer the distance between the fixation point and the joint surface, the longer the intra-canal graft portion without fixation and the greater tunnel widening proximal to the joint surface [9].

Therefore, the reasons for widening were closely correlated to the surgical technique, the femoral tunnel orientation [7,8,18,19] and the fixation device. Cortical fixations such as ZipLoop® favored “bungee” and “windscreen wiper” effects due to the distance between the anchorage system and the joint. Therefore, the graft micromovements inside the tunnel were impacted on a long portion of the tunnel.

Tunnel widening was of conical shape with the ZipLoop® device as reported with all cortical fixations [17]. However, due to its adjustable length, a long term bony preservation could be achieved. Custom-made tunnels were shorter thus reducing the distance between the top of the enlargement cone and the joint. No correlation between residual laxity and femoral tunnel widening could be established. The reason of the difference in terms of correlation with tunnel widening between residual laxity and IKDC scores remains unclear. One hypothesis could be that tunnel widening could mean a modification of at least one of the IKDC items, but not related to laxity.

Grafts appeared well implanted in their tunnel and the ZipLoop® fixation device had not loosened during the ligamentization process.

From a clinical point of view, functional subjective and objective IKDC scores were comparable to those reported in the literature whatever the ACL reconstruction technique. Our findings were compared with those reported by Lewis et al. [20] in his 2008 meta-analysis of 11 prospective randomized studies on ACL reconstruction using patellar tendon and hamstring tendon grafting. 911 patients had been included with a mean follow-up of two years. There was a higher percentage of patients rated IKDC A in our study (58.69% versus 35%) whereas both studies reported a similar rate of IKDC D (2.17% in our study, 6 percent in the Lewis meta-analysis). The objective IKDC scores were higher in our study than those from the study of Biau et al. [21] who reported 33% of the subjects rated IKDC A and 45% of the subjects rated IKDC B (for the STG tendon graft sub-group). The subjective IKDC score was 30% higher at one year. The SF36 score had also improved thus demonstrating a better quality of life after ACL reconstruction.

The cortical fixation of the graft provided satisfactory laximetry results comparable to those from the literature. Plaweski et al. [17]

Table 1

Preoperative and last follow up clinical results.

	Preoperative	Last follow up
IKDC objective score A	0	27
IKDC objective score B	2	17
IKDC objective score C	33	1
IKDC objective score D	11	1
IKDC subjective score	50 ± 14.9 (SD)	81.8 ± 17.3 (SD)
SF 36 score	70.94 ± 13.87 (SD)	86.56 ± 9.33 (SD)
GNRB laximetry	2.94 ± 2.38 mm (SD)	0.74 ± 1.92 mm (SD)

Table 2
Review of the literature on femoral tunnel widening after ACL reconstruction.

References	Follow-up	Femoral fixation	Measurement	Femoral tunnel widening	Correlation with laxity
Silva et al. [5]	3 months	Endobutton CL®	Scan	30% and 34% diameter enlargement	No
Kobayashi et al. [22]	6 months	Interference screw	Radiograph	36.7% of the cases (over 2 mm)	No
Jansson et al. [6]	2 years	Endobutton CL®	Radiograph	33% diameter enlargement	No
Fauno et al. [23]	1 year	Transfix	Radiograph	17% of the cases (over 2 mm)	No
		Endobutton CL®	Radiograph	43% of the cases (over 2 mm)	No
Giron et al. [9]	5 years	Mitek anchor	Radiograph	32% of the cases (over 2 mm)	No
Clatworthy et al. [3]	2 years	Endobutton CL®	Radiograph	47% area increase	No
		Interference screw	Radiograph	117% area increase	No
Klein et al. [18]	18,4 months	Cross pin	Radiograph	65.5% diameter enlargement	No
Kuskucu et al. [24]	12 months	Endobutton CL®	Radiograph	43.71% diameter enlargement	No
		Cross pin	Radiograph	32.71% diameter enlargement	No
Plaweski et al. [17]	4 years	Endobutton CL®	Radiograph	58% diameter enlargement	No
Our series	12 months	Ziploop®	Scan	49.32% diameter enlargement	No

reported a differential laximetry lower than or equal to two millimeters in 59% of the subjects when measurements were performed with the Telos and in 54.3% when using the KT-1000. In our series, 76% of the patients had a differential laxity lower than or equal to two millimeters at one year.

5. Conclusion

The Ziploop® cortical fixation technology in ACL reconstruction using a STG tendon graft resulted in a highly significant widening of the femoral tunnel. This enlargement, close to the joint line, was correlated to impaired clinical findings.

This surgical technique using the Ziploop® fixation demonstrated good functional and laximetric results, comparable with those reported with other femoral fixation devices for hamstring tendon grafts. It also demonstrated several benefits. The adjustable length of this cortical fixation technology allowed reducing the length of the drilled tunnels in order to displace the top of the cone close to the joint thus sparing bone stock.

The physiopathological mechanism of tunnel enlargement has been well described but the predictive factors of such phenomenon should be further investigated in order to better identify high risk patients.

Conflict of interest

The authors did not receive grants or outside fundings in support of their research for or in preparation of the manuscript entitled “The effect of femoral tunnel widening on one-year clinical outcome after anterior cruciate ligament reconstruction using Ziploop® technology for fixation in the cortical bone of the femur”. No commercial entity paid or directed, or agreed to pay or direct, any benefits to any research fund, foundation, educational institution, or other charitable or nonprofit organization with which the authors are affiliated or associated.

Supplementary data to this article can be found online at <http://dx.doi.org/10.1016/j.knee.2015.06.002>.

References

- Brown GA, Peña F, Grøntvedt T, Labadie D, Engebretsen L. Fixation strength of interference screw fixation in bovine, young human, and elderly human cadaver knees: influence of insertion torque, tunnel-bone block gap, and interference. *Knee Surg Sports Traumatol Arthrosc* 1996;3:238–44.
- Giurea M, Zorilla P, Amis AA, Aichroth P. Comparative pull-out and cyclic-loading strength tests of anchorage of hamstring tendon grafts in anterior cruciate ligament reconstruction. *Am J Sports Med* 1999;27:621–5.
- Clatworthy MG, Annear P, Bulow JU, Bartlett RJ. Tunnel widening in anterior cruciate ligament reconstruction: a prospective evaluation of hamstring and patella tendon grafts. *Knee Surg Sports Traumatol Arthrosc* 1999;7:138–45.
- Peyrache MD, Djian P, Christel P, Witvoet J. Tibial tunnel enlargement after anterior cruciate ligament reconstruction by autogenous bone-patellar tendon-bone graft. *Knee Surg Sports Traumatol Arthrosc* 1996;4:2–8.
- Silva A, Sampaio R, Pinto E. Femoral tunnel enlargement after anatomic ACL reconstruction: a biological problem? *Knee Surg Sports Traumatol Arthrosc* 2010;18:1189–94.
- Jansson KA, Harilainen A, Sandelin J, Karjalainen PT, Aronen HJ, Tallroth K. Bone tunnel enlargement after anterior cruciate ligament reconstruction with the hamstring autograft and endobutton fixation technique. A clinical, radiographic and magnetic resonance imaging study with 2 years follow-up. *Knee Surg Sports Traumatol Arthrosc* 1999;7:290–5.
- L'Insalata JC, Klatt B, Fu FH, Harner CD. Tunnel expansion following anterior cruciate ligament reconstruction: a comparison of hamstring and patellar tendon autografts. *Knee Surg Sports Traumatol Arthrosc* 1997;5:234–8.
- Höher J, Möller HD, Fu FH. Bone tunnel enlargement after anterior cruciate ligament reconstruction: fact or fiction? *Knee Surg Sports Traumatol Arthrosc* 1998;6:231–40.
- Giron F, Aglietti P, Cuomo P, Mondanelli N, Ciardullo A. Anterior cruciate ligament reconstruction with double-looped semitendinosus and gracilis tendon graft directly fixed to cortical bone: 5-year results. *Knee Surg Sports Traumatol Arthrosc* 2005;13:81–91.
- Fahey M, Indelicato PA. Bone tunnel enlargement after anterior cruciate ligament replacement. *Am J Sports Med* 1994;22:410–4.
- Simonian PT, Erickson MS, Larson RV, O'kane JW. Tunnel expansion after hamstring anterior cruciate ligament reconstruction with 1-incision EndoButton femoral fixation. *Arthroscopy* 2000;16:707–14.
- Webster KE, Feller JA, Hameister KA. Bone tunnel enlargement following anterior cruciate ligament reconstruction: a randomised comparison of hamstring and patellar tendon grafts with 2-year follow-up. *Knee Surg Sports Traumatol Arthrosc* 2001;9:86–91.
- Zijl JA, Kleipool AE, Willems WJ. Comparison of tibial tunnel enlargement after anterior cruciate ligament reconstruction using patellar tendon autograft or allograft. *Am J Sports Med* 2000;28:547–51.
- Lefevre N, Bohu Y, Naouri JF, Klouche S, Herman S. Validity of GNRB® arthrometer compared to Telos™ in the assessment of partial anterior cruciate ligament tears. *Knee Surg Sports Traumatol Arthrosc* 2014;22:285–90.
- Fules PJ, Madhav RT, Goddard RK, Newman-Sanders A, Mowbray MAS. Evaluation of tibial bone tunnel enlargement using MRI scan cross-sectional area measurement after autologous hamstring tendon ACL replacement. *Knee* 2003;10:87–91.
- Robinson J, Huber C, Jaraj P, Colombet P, Allard M, Meyer P. Reduced bone tunnel enlargement post hamstring ACL reconstruction with poly-L-lactic acid/hydroxyapatite bioabsorbable screws. *Knee* 2006;13:127–31.
- Plaweski S, Rossi J, Merloz P. Anterior cruciate ligament reconstruction: assessment of the hamstring autograft femoral fixation using the EndoButton CL. *Orthop Traumatol Surg Res* 2009;95:606–13.
- Klein JP, Lintner DM, Downs D, Vavrenka K. The incidence and significance of femoral tunnel widening after quadrupled hamstring anterior cruciate ligament reconstruction using femoral cross pin fixation. *Arthroscopy* 2003;19:470–6.
- Ma CB, Francis K, Towers J, Irgang J, Fu FH, Harner CH. Hamstring anterior cruciate ligament reconstruction: a comparison of bioabsorbable interference screw and endobutton-post fixation. *Arthroscopy* 2004;20:122–8.
- Lewis PB, Parameswaran AD, Rue J-PH, Bach Jr BR. Systematic review of single-bundle anterior cruciate ligament reconstruction outcomes: a baseline assessment for consideration of double-bundle techniques. *Am J Sports Med* 2008;36:2028–36.
- Biau DJ, Tournoux C, Katsahian S, Schranz P, Nizard R. ACL reconstruction: a meta-analysis of functional scores. *Clin Orthop Relat Res* 2007;458:180–7.
- Kobayashi M, Nakagawa Y, Suzuki T, Okudaira S, Nakamura T. A retrospective review of bone tunnel enlargement after anterior cruciate ligament reconstruction with hamstring tendons fixed with a metal round cannulated interference screw in the femur. *Arthroscopy* 2006;22:1093–9.
- Fauno S, Kaalund S. Tunnel widening after hamstring anterior cruciate ligament reconstruction is influenced by the type of graft fixation used: a prospective randomized study. *Arthroscopy* 2005;21:1337–41.
- Kuskucu SM. Comparison of short-term results of bone tunnel enlargement between EndoButton CL and cross-pin fixation systems after chronic anterior cruciate ligament reconstruction with autologous quadrupled hamstring tendons. *J Int Med Res* 2008;36:23–30.