

The Comparative Role of the Anterior Cruciate Ligament and Anterolateral Structures in Controlling Passive Internal Rotation of the Knee: A Biomechanical Study



Nicolas Ruiz, M.D., German J. Filippi, M.D., Bertrand Gagnière, M.D., M.Sc.,
Mark Bowen, M.D., and Henri E. Robert, M.D.

Purpose: To determine the respective functions of the anterior cruciate ligament (ACL) and the anterolateral structures (ALSs) in controlling the tibia's passive internal rotation (IR) with respect to the femur, under uniaxial rotation. **Method:** To test the function of the ACL and the anterolateral ligament (ALL) in IR, we designed a sequential transection study of the ACL and the anterolateral structures (including the ALL) in 24 cadaveric knees divided in 2 groups. Two sequences were conducted successively: group 1 (12 knees) in which the ACL was sectioned first followed by the ALS, and group 2 (12 knees) with reversed transections. Each knee, in neutral rotation position and at flexion angle of 30°, was subjected to a 5 Nm torsion torque of IR. IR was measured using a rotatory laximeter, the Rotam with a gyroscope's measurement accuracy of 0.1°. Laxities were compared using paired t test within each group and using t test between groups. Fisher exact test was used to compare proportions. **Results:** In group 1, IR increased from 22.1° ± 10.6° to 25.7° ± 10.9° after ACL transection then to 28.1° ± 10.5° after we sectioned the ALS. In group 2, IR increased from 22.5° ± 8.9° to 25.2° ± 8.4° after sectioning the ALS, then to 29.1° ± 8.8° after we sectioned the ACL. Total postsectioning increase in IR was 6.4° ± 2° in group 1, and 6.55° ± 0.9° in group 2. The IR increase after each stage of transection and final IR were statistically significant ($P < .001$). **Conclusions:** In a pure rotational cadaveric test model, the ACL and the ALS contribute to resistance to passive IR of the knee. **Clinical Relevance:** In some specific clinical cases, peripheral lesions may be considered, and injuries to these structures may need to be addressed to improve results controlling postoperative IR.

See commentary on page 1063

Control of internal rotation (IR) in the knee is dependent on the cruciate ligaments, peripheral ligament structures, and the hamstring muscles.¹ Over the last 20 years, substantial progress has been made in the anatomic reconstruction of the anterior cruciate ligament (ACL).² "Anatomic" double-bundle

reconstructions (ADBRs) have been proposed in place of single-bundle reconstructions or anatomic single-bundle reconstructions (ASBRs) to ensure better rotational control and reduce the frequency of a persistent pivot shift.³⁻⁷ Recent studies showed no significant difference between ADBR and ASBR groups for clinical outcomes (Lysholm score and subjective IKDC score) or for laximetric results (anterior tibial translation and pivot shift), when an individualized reconstruction is used.^{8,9} Residual sagittal laxity remains, and the presence of pivot shift with ADBR seems to be just as frequent (around 10%) as in cases of ASBR.^{8,9} In a meta-analysis on 4 randomized controlled trials, Meredick et al.⁹ concluded that "double-bundle reconstruction does not result in clinically significant differences in KT-1000 arthrometer or pivot-shift testing."

Because the ACL reconstruction (ACLR) technique, meaning the intra-articular graft itself, does not control the pivot shift alone, we should consider some possible

From the University Hospital Orthopaedic Department (N.R.), Angers, France; Orthopaedic Department, North Mayenne Hospital (N.R., G.J.F., B.G., H.E.R.), Mayenne, France; Hospital Universitario CEMIC (G.J.F.), Buenos Aires, Argentina; and NorthShore Orthopedic Institute (M.B.), Chicago, Illinois, U.S.A.

The authors report that they have no conflicts of interest in the authorship and publication of this article.

Received September 13, 2015; accepted February 8, 2016.

Address correspondence to Henri E. Robert, M.D., North Mayenne Hospital, Orthopaedic Department, 53100 Mayenne, France. E-mail: henri.robert@wanadoo.fr

© 2016 by the Arthroscopy Association of North America

0749-8063/15880/\$36.00

<http://dx.doi.org/10.1016/j.arthro.2016.02.017>

neglected damage to the anterolateral structures (ALS). As the ACLR may fail to control rotational instability, patients having ACLR may benefit from concomitant reconstruction of the anterolateral ligament (ALL).¹⁰ The addition of a lateral extra-articular tenodesis (LET) to the intra-articular reconstruction may be beneficial.¹⁰ The main LET techniques (Lemaire and Macintosh procedures) were first described more than 40 years ago, often as isolated repairs.^{11,12} Both techniques harvest a strip of the iliotibial band and fix it to the lateral femoral condyle after crossing the lateral collateral ligament (LCL). Nowadays, these tenodeses are usually performed in association with an ASBR.^{7,13} The interest in lateral reconstructions prompted a rediscovery and study of the anterolateral structures (ALS) of the knee.^{1,14} In 1976, Hughston wrote: "the anterolateral rotational instability, as shown by the jerk test, is linked to a lesion of the lateral capsular ligament, but may be accentuated by a lesion of the anterior cruciate ligament."¹⁵ The role of the peripheral structures was shown in several studies in the 1980s and 1990s. Unrepaired secondary stabilizers have been noted as a cause for reconstruction failure.^{15,16}

The existence of a specific structure in the knee's lateral capsule was discovered by dissections performed in 1879 by Paul Segond. He described it as "a resistant, pearly, fibrous band, which, in an exaggeration of internal rotational movement, is always subjected to an extreme degree of tension" as well as an avulsion fracture now named the "Segond fracture."¹⁷ This "recently" described structure was named the "anterolateral ligament" (ALL) by Vieira et al.¹⁸ in 2007. The ALL has been the subject of many recent publications although there has not always been agreement with each other in the anatomic origins.^{14,18-23} Van der Watt et al.²⁴ recently published a systematic review on the ALL. The ALL was found to originate from the region of the lateral epicondyle and is inserted on the proximal tibia, midway between the Gerdy tubercle and the fibular head. Some researchers reported only a capsular thickening in 30% of the cadaveric specimens rather than a distinct ligament when evaluating the macroscopic anatomy, histology, and radiology of the anterolateral capsule.²⁵ The primary function of the ALL is to provide anterolateral stability to the knee, preventing the tibia from anterior subluxation relative to the distal femur. This function may play an important role in preventing the pivot-shift phenomenon, along with the ACL. Some authors highlighted the respective roles of both ACL and ALL in controlling the knee's passive IR.^{26,27} For Parsons et al.,²⁶ the ACL force contribution decreases as flexion angle increases while the ALL contribution increases. For Spencer et al.,²⁷ the ALL acts as a secondary stabilizer, in combination with the ACL as the primary stabilizer, to anterolateral rotation.

The purpose of this study was to determine the respective functions of the ACL and the ALS in controlling the tibia's passive IR with respect to the femur, under uniaxial rotation.

The hypothesis was that the ACL and the ALS transections increase the knee's passive IR significantly, when it is submitted to a uniaxial torsion torque, and that they play a synergistic role in resisting passive IR.

Methods

Specimen Preparation

In the anatomy laboratory (Medical School of Rennes, France), we tested 24 cadaveric lower limbs, unpaired and fresh-frozen. Written consent from the donor for their use for educational and research purposes was available for each specimen. The lower limbs were collected by disarticulation at the hip and kept frozen at -20°C . All specimens were thawed at room temperature (20°C) for 1 day before experimentation and all soft tissues around the knee were kept intact. The knees were mobilized in flexion, extension, and rotation to ensure that they were flexible, able to flex to at least 130° , and were stable for clinical testing in frontal and sagittal planes. Inclusion criteria were stable and mobile knees, and exclusion criteria were signs of ligamentous injuries, bone abnormalities, severe osteoarthritis, or previous surgery. Six knees out of 30 initially selected were excluded by the surgeon who performed the dissection. After this process, 10 male and 14 female cadaveric knees, with an average age of 76 years (47 to 92) were tested.

An orthopaedic surgeon (H.R.), experienced in knee surgery, assessed the specimens and performed the dissections. An anteromedial vertical arthrotomy of 3 to 4 cm was performed to reach the surface of the tibia, check the macroscopic integrity of the ACL, and confirm the absence of tibiofemoral osteoarthritis or notch osteophytes. The whole ACL was dissected at the midportion and No. 2 Vicryl sutures were tied around it. We did not attempt to separate the AM and PL bundles, especially as isolated bundle sectioning has little effect on IR.^{26,27} The capsulotomy was left partially open for the time of testing. To reach the ALS, the lower limb was set in a supine position with a sandbag under the thigh. Three bony landmarks were marked before incision: the head of the fibula, the lateral epicondyle, and Gerdy tubercle. A cutaneous and subcutaneous incision of 8 cm was made, extending from the lateral epicondyle to a point located between the Gerdy tubercle anteriorly and the head of fibula posteriorly, on the theoretical axis of the ALL. The iliotibial band (layer I for Claes et al.¹⁹) was incised longitudinally and retracted anteriorly to visualize the ALS. The LCL was located by palpating the ligament with the knee in slight varus-flexion, and its insertion

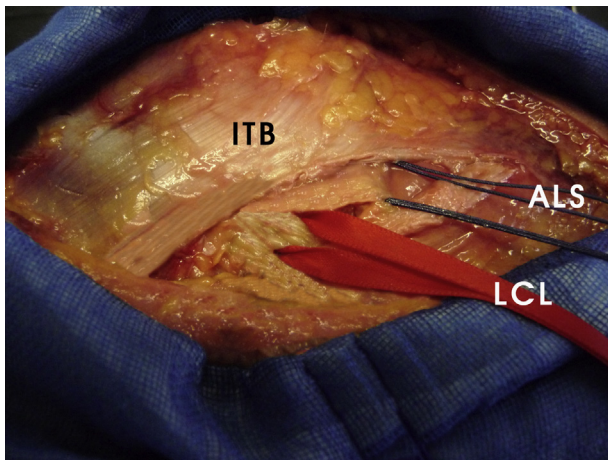


Fig 1. General anatomic lateral view of a right knee. The iliotibial band (ITB) has been incised, and the lateral collateral ligament (LCL) (red tape) has been identified. Through use of both an inside-out and outside-in anatomic dissection, all the fibers of the lateral capsule, including the anterolateral ligament, coursing from this point to the lateral edge of the patellar ligament, were identified as the anterolateral structures (ALS) and dissected (blue thread of Vicryl).

onto the fibular head was identified. The superficial lamina of the capsule encompassing the LCL was incised anteriorly and parallel to the LCL next to the superior edge of the lateral meniscus, and then the capsular fibers were incised.¹⁹ Through use of both an inside-out and outside-in anatomic dissection, all the fibers of the lateral capsule including the ALL (Layer III of Claes et al.), coursing from this point to the lateral edge of the patellar ligament were identified as the ALS and dissected. In this study, we did not attempt to dissect out the ALL from the capsule. We dealt with the structures located below the ITB as a unit as described by Hugston et al., Dodds et al., or Monaco et al., that is, the anterolateral capsulo-ligamentous elements: ALS, including the Kaplan fibers (Fig 1).^{15,21,28}

Laximetry Device

We used a noninvasive and static rotational knee laxity device, called the Rotam (GeNouRoB, Laval, France) (Fig 2). The Rotam is derived from the Rotameter, which has been validated and widely used in clinical practice for a number of years.²⁹⁻³¹ It allows the isolated rotations (internal and external) of the knee to be measured when subjected to a torsion torque of 0 to 8 Nm. The Rotam does not record the anterior tibial translation, which is a major component of the combined displacements (anterior translation, rotations, valgus) causing the pivot shift.^{13,32,33} The Rotam possesses a highly precise gyroscope with a measurement accuracy of 0.1°. The lower limb was placed on a thermoformed support at 30° of flexion, to imitate the dial test.²⁹ A calibrated, femoral strap fixed the thigh at

high force (above 70 N). The foot and ankle were attached to a dual bootstrap, providing a stationary block under the tibia. The initial knee position (position zero) was defined by “the patella at the zenith” and the foot-ankle block was in a natural resting position of the leg (usually in slight lateral rotation) controlled by the absence of constraint on the boot sensors. The initial position of the lower limb obtained after complete stabilization was not further modified during all the recording stages. The measurements of the IR induced by the Rotam were measured from this neutral position. The tibia below the femur was subjected to a torque (0 to 5 Nm) by an electric engine (DC Motor Maxon, Sachseln, Switzerland; engine characteristics: tension, 24 V; power, 46 W; couple, 11 tr/mm), a couple torque of 5 Nm was chosen to simulate the clinical practice.²⁹⁻³¹ The femorotibial induced rotations were recorded as a curve, usually between -5 and +5 Nm. Differences in IR (intact knee *v* transected ligament knee) were calculated. We did not examine the changes in external rotation as part of this study, which are usually very slight and of little significance.³¹ We calculated the increase for each stage in degrees and as a percentage.

Testing Protocol

We performed 2 series of sequential transections. Group 1 included 12 knees (7 female, 5 male) and the ACL was sectioned first in its midportion and then the ALS (approximately 2 cm long) were sectioned. Group 2 included 12 knees (9 female, 3 male) and the ALS were sectioned first, followed by the sectioning of the ACL. The sections were created with the help of No. 2




Fig 2. The Rotam device. The lower limb was placed on a thermoformed support at 30° of flexion. The thigh was fixed by a calibrated, femoral strap. The foot and ankle were attached to a dual bootstrap. The initial knee position was defined by “the patella at the zenith” and the foot-ankle block was in a natural resting position of the leg (usually in slight lateral rotation). The internal rotations induced by the electric engine (torque from 0 to 8 Nm) were measured from this resting position.

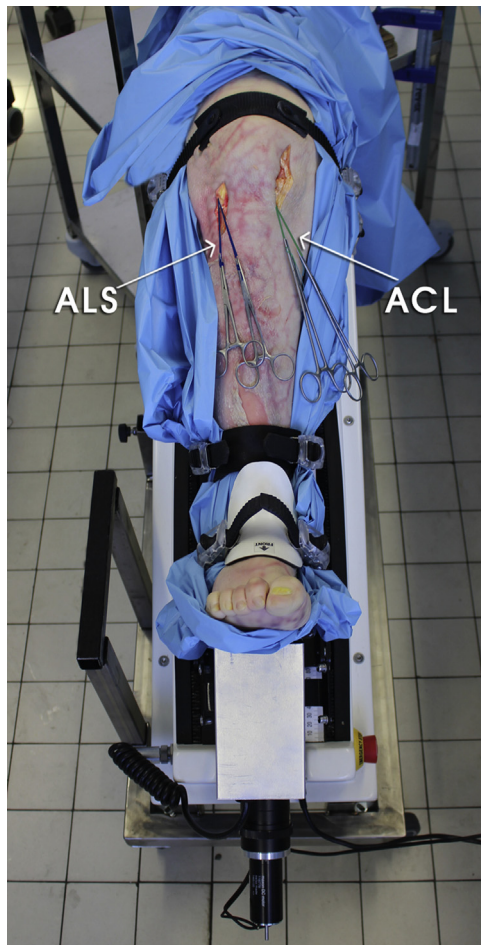


Fig 3. Experimental setup showing a left lower limb on the Rotam. The anterior cruciate ligament (ACL) and the anterolateral structures (ALS) have each been indicated using a loop of No. 2 Vicryl and a clamp. In group 1, the ACL was sectioned first in its midportion, and then the ALS were sectioned. All measurements were recorded 3 times, and the mean value taken as the final result in each case.

Vicryl sutures (Ethicon), doubled up and used in the same manner as a Gigli saw (Fig 3). To account for any viscoelastic effects of the tissues, all measurements were recorded 3 times and the mean value taken as the final result in each case. The results were expressed as angulation/torque curves (Fig 4 A and B).

Statistical Analysis

Means and standard deviations were estimated for continuous data. Within each group, means were compared using paired *t* test to estimate the sequential transection effects. Then, to assess if the order of the transections had an influence on the observed laximetry, mean differences after each transection (ACL and ALS) were compared between both groups using *t* test. Fisher exact test was used to compare proportions. All comparisons were performed at a 5% significance level.

In case of nonsignificant results, power was a posteriori estimated using 2 complementary ways: real

power of the study for the observed difference and minimum difference that should have been observed to have an 80% power.

Results

Groups 1 and 2 were comparable in terms of age (76.4 and 76.1 years respectively, $P = .95$) and sex (33.3% v 58.3% of males respectively, $P = .41$) (Table 1). In group 1, the average IR of the intact knee was $22.1^\circ \pm 10.6^\circ$. After the section of the ACL, the average IR increased to $25.7^\circ \pm 10.9^\circ$ ($P < .001$), and after the section of the ALS, the average IR of the transected knee was $28.1^\circ \pm 10.5^\circ$ ($P < .001$). The total gain in IR after ACL and ALS sections was $+6.4^\circ \pm 2^\circ$ ($P < .001$) (Figs 4 A and 5, Table 2). In group 2, the average initial rotation of the intact knee was $22.5^\circ \pm 8.9^\circ$. After transection of the ALS, the average IR increased to $25.2^\circ \pm 8.4^\circ$ ($P < .001$). When the section of the ACL was added, the average final IR was $29.1^\circ \pm 8.8^\circ$ ($P < .001$). The total gain in IR after the section of the ALS and the ACL was $+6.6^\circ \pm 0.9^\circ$ ($P < .001$) (Figs 4B and 5, Table 3).

In comparing the 2 groups, the average initial rotations were very similar ($22.1^\circ \pm 10.6^\circ$ and $22.5^\circ \pm 8.9^\circ$ for group 1 and 2 respectively); the IR increased significantly after each stage of transection ($P < .001$) and there was a significant gain in IR after ACL and ALS transection compared with the intact knee ($P < .001$). There was no significant difference in the gain in IR after the isolated ACL section in the 2 groups ($P = .51$) or in the gain in IR after isolated section of the ALS ($P = .56$). There was no difference in the final gain between the 2 groups ($P = .80$) (Table 1).

Discussion

The most important finding of this study was that the ALS, which include the ALL, resists passive IR of the knee. Our findings support the synergistic role of the ACL and the ALS as a restraint to IR. At 30° of flexion, IR of the tibia with respect to the femur was increased by 12% on average after section of the ALS and by 17% on average after section of the ACL. The passive control of IR of the tibia with respect to the femur is therefore the result of the combined action of the ALS and the ACL. The transection of both elements causes a significant increase in IR of almost 30%. There was no statistically significant difference in IR gain between the 2 groups ($P = .80$). The order of the sections did not have an effect on the total increase in IR, which suggests that the ALS and the ACL are independent and synergistic. However, this absence of difference may be due to a lack of power. Indeed, for ACL and ALS sections, the powers of our comparisons were 11% and 10%, respectively. A power of 80% would have been available for observed differences of 1.28° and 1.25° respectively. Nevertheless, the observed differences

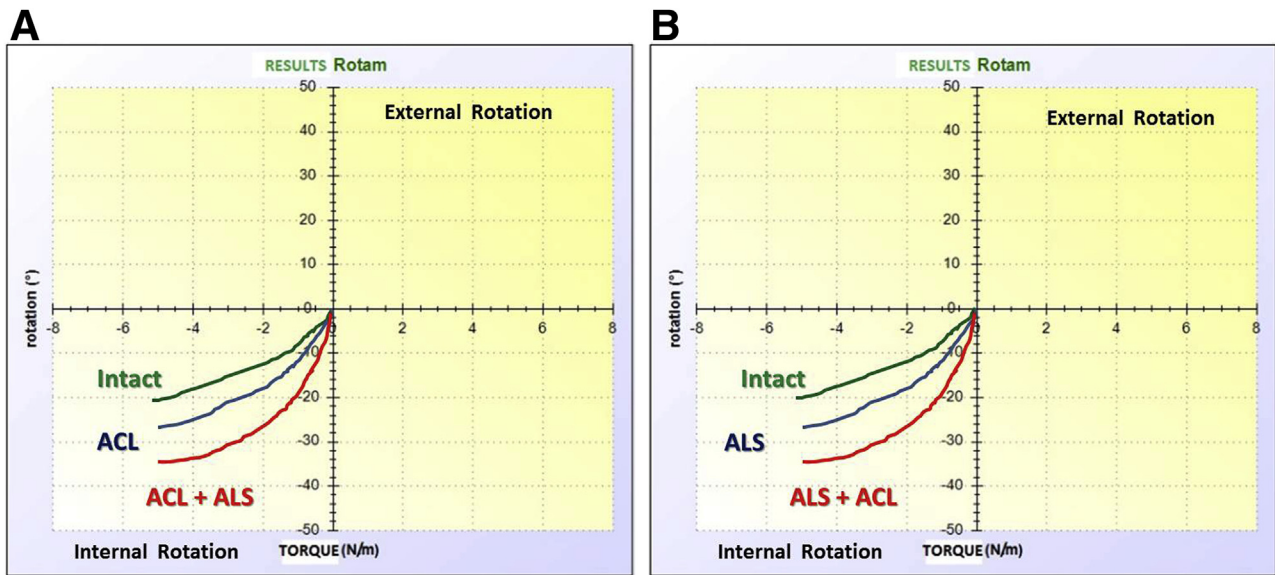


Fig 4. (A) Torsion torque (Nm) versus internal rotation (in degrees). The curves represent the range of internal rotation in the intact knee (green curve), after sequential sections of the anterior cruciate ligament (ACL) (blue curve) and finally after section of the anterolateral structures (ALS) (red curve) (group 1). The mean value of 3 tests was taken as the final result in each condition (B). Torsion torque (Nm) versus internal rotation (in degrees). The curves represent the range of internal rotation in the intact knee (green curve), after sequential sections of the ALS (red curve) and finally after section of the ACL (blue curve) (group 2).

themselves were small (0.34° and 0.29°, respectively), and we consider that either the statistical absence of difference or these small differences are physiologically consistent. As a comparison, the total difference between both groups after 2 sections was very small (0.16°).

Several cadaveric works have studied the role of the ACL in controlling the IR and their results were very similar to ours. An optical navigation system and the Rotameter were used in a controlled laboratory study to evaluate the influence of the ACL and especially the posterolateral bundle (PLB) on tibiofemoral rotation.³⁰ Isolated resection of the PLB or total resection of the ACL yielded significant increase in IR at 5 and 10 Nm of torque (+5° with Rotameter, +3° with navigation).³⁰ In a laboratory study, Noyes et al.³² obtained an increase of 1.6° ± 1.1° after section of the ACL. Kondo et al.³³ showed in a laboratory study that cutting both

bundles significantly increased the IR, reaching +3.8° near knee extension, under 5 Nm rotation torque. Kanamori et al.³⁴ in a cadaveric study using robotic/universal force–moment sensor testing system (UFS) registered an increase of 1.3° of IR of the knee submitted to an isolated tibial torque of 10 Nm. Diermann et al.³⁵ studied tibiofemoral rotation in cadaveric knees using the Genucom and found significant increases of IR after cutting the ACL (+3° at 10° of knee flexion). Using a robot, they studied the effect of combined 10 Nm valgus and 4 Nm IR moment on tibiofemoral laxity. They again found only 2° mean increase in IR after cutting the whole ACL.³⁵ An increase of around 4°

Table 1. Demographic Data and Mean IR Increase in Intact Knees, After Each Section in Both Groups and Final Increase

	Group 1	Group 2	P Value
Mean age, years (SD)	76.42 (12.13)	76.08 (13.64)	.95
Male, %	33.3	58.33	.41
IR increase, °, after ACL or ALS section, mean (SD)	3.58 (1.24)	3.92 (1.29)	.51
Increase, °, after ALS + ACL section, mean (SD)	2.40 (1.37)	2.69 (1.01)	.56
Final difference, °/intact knee, mean (SD)	6.39 (2.04)	6.55 (0.89)	.80

ACL, anterior cruciate ligament; ALS, anterolateral structures; IR, internal rotation; SD, standard deviation.

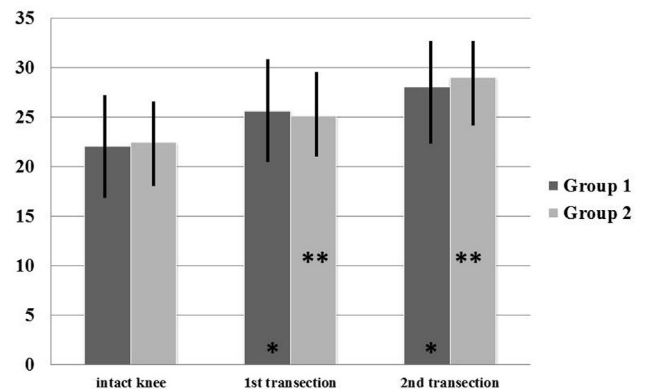


Fig 5. Internal rotations (IR) (degrees) after sequential transection of the anterior cruciate ligament and the anterolateral structures in groups 1 and 2. The asterisks indicate statistical significance after each section in both groups.

Table 2. Group 1 Demographic and Internal Rotation Data (Intact, After Transection of the ACL, and Transection of the 2 Structures)

Case	Sex	Age, yr	Intact, initial IR, mean, °	After Transection of the ACL			After Transection of the ACL and ALS			Final Laxity Increase	
				IR, mean, °	Increase, mean, °	Increase, mean, %	Final IR, mean	Increase, mean, °	Increase, mean, %	IR increase/ initial IR, mean, °	IR increase/ initial IR, mean, %
1	Female	84	23.9	27.1	3.2	13.4	30.2	3.1	11.4	6.3	26.4
2	Female	81	13.7	16.8	3.1	22.6	19	2.2	16	5.3	38.7
3	Female	79	29.6	33.8	4.2	14.2	35.2	1.4	4.7	5.6	18.9
4	Male	59	18.5	22.6	4.1	22.2	27	4.35	23.5	8.5	45.9
5	Male	59	12.6	16.9	4.3	34.1	22.4	5.5	43.7	9.8	77.8
6	Male	74	42.7	45.5	2.8	6.6	46.7	1.2	2.8	4	9.4
7	Male	91	14.2	17.4	3.2	22.5	19.1	1.7	12	4.9	34.5
8	Female	92	34.3	41.3	7	20.4	43.6	2.3	6.7	9.3	27.1
9	Female	89	8.3	11.5	3.2	38.6	13.6	2	24.1	5.2	62.7
10	Female	76	28	30.8	3.4	12.1	31.4	5	17.9	8.4	30
11	Female	74	27.8	30.3	2.5	9	32.8	2.5	9	5	18
12	Female	59	12	14.6	2.5	20.8	16.4	1.9	15.8	4.4	36.7
Mean		75.2	22.1	25.7	3.6	16.4	28.1	2.8	12.5	6.4	28.9
SD		12.1	10.6	10.9	1.2	9.6	10.5	1.4	11.1	2	19.3
Range		59-92	8.3-43.7	11.5-45.5	2.5-4.3	12.1-38.6	13.6-46.7	1.2-5.5	2.8-43.7	4-9.8	9.4-62.7
P values				ACL/intact			ACL+ALS/ACL			ACL+ALS/intact	
				P < .001			P < .001			P < .001	

ACL, anterior cruciate ligament; ALS, anterolateral structures; IR, internal rotation; SD, standard deviation.

of IR was obtained by Markolf et al.³⁶ at 30° of flexion, under a tibial torque of 5 Nm.

When carrying out this study, we opted not to attempt the difficult task of separating the 2 bundles. Additionally, some old and new anatomic studies have not supported the presence of 2 bundles. Numerous authors reported that the intraligamentous part of the ACL is a collection of individual fascicles that fan out over a broad flattened area with no evidence for

2 separate bundles.³⁷⁻³⁹ For Smigielski et al.,³⁹ the “double-bundle effect” was created by the twisted “flat ribbon like” structure of the ACL from femoral to tibial, which leads to the impression of 2 bundles when the knee was flexed from 0° to 90°.

All of this laboratory work shows that only complete section of the ACL results in a moderate increase in IR. It seems logical to research other structures that are involved in rotational control. The role of the ALS in IR

Table 3. Group 2 Demographic and Internal Rotation Data (Intact, After Transection of the ALS, and Transection of the 2 Structures)

Case	Sex	Age, yr	Intact, initial IR, mean, °	After Transection of the ACL			After Transection of the ACL and ALS			Final Laxity Increase	
				IR, mean, °	Increase, mean, °	Increase, mean, %	Final IR, mean, °	Increase, mean, °	Increase, mean, %	IR increase/ initial IR, mean, °	IR increase/ initial IR, mean, %
1	Female	78	16.2	18.5	2.3	14.2	23.3	4.8	29.6	7.1	43.8
2	Male	78	16.1	18.8	2.7	16.8	20.8	2	12.4	4.7	29.2
3	Female	83	14.4	18.9	4.5	31.3	22.3	3.4	23.6	7.9	54.9
4	Male	61	14.4	16.3	1.9	13.2	22.4	6.2	42.7	8	55.6
5	Male	93	18.5	21	2.5	13.6	24.6	3.6	19.7	6.1	33.2
6	Male	91	31.6	34.6	3	9.3	37.9	3.3	10.4	6.3	19.8
7	Female	60	27.8	30.6	2.8	9.9	34.1	3.5	12.7	6.3	22.6
8	Male	81	25.2	28.6	3.4	13.6	32.2	3.6	14.2	7	27.8
9	Male	81	36.4	37.6	1.3	3.6	42.8	5.2	14.2	6.5	17.8
10	Female	86	38	39.1	1	2.6	44.9	5	13.1	6	15.8
11	Male	47	14.5	17.6	3.1	21.5	21	3.5	24.2	6.6	45.7
12	Female	74	17.1	21	3.9	22.8	23.3	2.3	13.5	6.2	36.3
Mean		76	22.5	25.2	2.7	12	29.1	3.9	17.2	6.6	29.2
SD		13.6	8.9	8.4	1	8.1	8.8	1.2	9.5	0.9	13.9
Range		47-93	14.4-38.3	16.3-39.8	1-4.5	2.6-31.3	20.8-44.9	2-6.2	10.4-42.7	4.7-8	15.8-55.6
P values				ALS/intact			ALS+ACL/ALS			ALS+ACL/intact	
				P < .001			P < .001			P < .001	

ACL, anterior cruciate ligament; ALS, anterolateral structures; IR, internal rotation; SD, standard deviation.

control has been long known, but has been largely overlooked for 20 years when treating ruptures of the ACL. Forty years ago, Jack Hughston described the anterolateral capsular ligament as a “strong and major lateral static support for the knee around 30° of flexion.”¹⁵ Werner Muller later identified “the femoro-tibial antero externe ligament” as a thickening of the capsule and one of the damaged elements in the case of anterolateral rotatory instability.¹ For Vieira et al.,¹⁸ “the deep layer of the lateral structure of the knee has a very well-defined ligament structure, which starts from the supraepicondylar region and inserts laterally to the Gerdy’s tubercle. In fact it acts as a true anterolateral ligament.” Several anatomic studies were published a number of years ago on the ALL, but many disparities remained regarding the exact site of the femoral origin, the existence (or not) of a lateral meniscal attachment, the individualisation (or not) of the capsule’s ALL.¹⁴⁻²³ These disparities are explained by the existence of many anatomic variations.⁴⁰

To our knowledge, only a few studies have been published on the relative importance of the ACL and the ALS in controlling IR. Parsons et al.²⁶ performed a laboratory study on 11 cadaveric knees subjected to 134 N of anterior drawer at flexion angles between 0° and 90° and separately to 5 Nm of IR at the same flexion angles. At a flexion angle of 30°, the contributions of the ACL and ALL were equivalent, which is confirmed by our results. Above 30°, the contribution of the ALL exceeded that of the ACL. Monaco et al.²⁸ recorded IR in 10 intact cadaveric knees, after section of the ACL and after section of the ALS, using a computer navigation system (OrthoPilot, B-Braun) at 30° knee flexion. Section of the ACL produced a minor and nonsignificant increase in IR (+3.2°), but anterolateral lesion significantly increased IR (+5.5°) at all grades of knee flexion. The additional lesion to the anterolateral zone resulted in an increase in the grade of the pivot shift.²⁸ Spencer et al.²⁷ investigated the effect of ACL and ALL transection on rotational knee kinematics on 12 cadaveric knees with 2 rigid bone markers (Optotrak Certus). Sectioning the ACL and the ALL significantly increased IR (+2° ± 1.5° and +4° ± 3°, respectively).²⁷ Our results are in concordance with those of Parsons et al.,²⁶ Monaco et al.,²⁸ and Spencer et al.²⁷ They all reported that knee flexion up to 90° causes the ALL to tension as they showed that an increase in length corresponds to a tightening of the ALL. Dodds et al.¹³ found that the ALL behavior was close to isometric from 0° to 60° and then shortened. Considering that the ALL stretching under flexion differs from the behavior of the ACL, which stretches under extension, these 2 ligaments, ALL and ACL, seem to be complementary.

The findings of our study show that the ALS are an important stabilizer to IR of the knee in conjunction with the ACL. Our hypothesis on the synergistic

function of these 2 structures is confirmed. For Lutz et al.,²³ the capsuloligament structure could be named “the anterolateral corner” as it is involved in anterolateral laxity control, just as the posterolateral corner is in posterolateral laxity control. With the Rotam device, we were not able to measure the simultaneous tibial translation, which is one of the indispensable components of the pivot shift.^{15,32,34,41}

It is well known that some patients with an ACLR may be found to have a positive pivot-shift test (grade 2 as a clunk and grade 3 as a subluxation).³⁻⁵ Injuries of the ACL are frequently associated with mild tears of the anterolateral or posterolateral capsular ligaments, with or without bony avulsion (Segond fracture).²⁸ In chronic ACL insufficiency, a progressive stretching or a nonhealing of the ALS may occur. It is possible that these injuries to the ALS were not appreciated at the index procedure.¹⁶ George et al.¹⁶ noted that a failure to treat concomitant injuries to the secondary restraints places increased stress on the reconstructed ACL and can be a reason for failure. A LET in addition to the ACL graft may be beneficial by reducing the load experienced by the intra-articular graft and reducing anterior translation and IR.^{42,43} The location of the ALS, away from the central pivot, provides them with a greater lever arm for controlling knee rotation than the intra-articular reconstruction. Several LET techniques have been described (Lemaire’s and MacIntosh’s techniques).^{11,12} They harvest an isolated strip (8 × 1 cm) of the posterior fibers of the ITB that is left attached to the tibia. The strip is then passed deep to the LCL and reattached posteriorly to the femoral insertion of the LCL (Lemaire’s technique). Other authors developed more “anatomic and isometric ALL reconstructions” based on the description of the ALL footprints to replicate the triangular shape of the native ALL.^{44,45}

The benefit of the association of a LET with ACL reconstruction (ACLR) remains controversial. Among 8 randomized studies, 3 concluded that the results between treatment groups were nonsignificant, 4 were in favor of LET for reduction of the pivot-shift test, and 1 was in favor of ACLR alone.⁴⁶ This systematic review concluded that the addition of LET to ACLR results in a statistically significant reduction in rotational laxity, as measured by the pivot-shift test but failed to show better clinical outcomes in favor of the LET plus ACLR. Moreover, for some authors, LET may cause stiffness, patellofemoral crepitation, cosmetic problems, and degenerative changes in the lateral compartment.⁴⁷ For some authors, candidates for combined ACLR and LET are those with chronic ACL lesion, high-level athletes in pivoting sports, patients with grade 3 pivot-shift or revision cases.^{10,46,47} The quantification of the pivot-shift testing using software loaded on a tablet computer can be used preoperatively to help adjust

individualized ACLR, intra-articular reconstruction alone, or combined intra plus LET.⁴⁸

Strengths

The strengths of this study were that entire lower limbs were used and the external torque was applied using a precise and accurate device, the Rotam. In this study, we did not attempt to individualize the ALL. We sectioned the anterolateral capsule elements as a single unit, in front of the LCL, including the ALL. The sections were made above the lateral meniscus, preserving the ITB (Fig 1). This allowed for reliable indisputable complete sectioning of the ALL, a variable fibrous thickening of the anterolateral capsule.

Limitations

There are several limitations: the lack of measured rotation beyond 30° of flexion, the lack of simultaneous measurement of the translation caused by the sequential sections, as this is not possible with the Rotam and the sample size. The specimens have been tested under 5 Nm of internal torque, which is small compared with the actual loads being applied to the knees during sports. It is possible that our conclusions on the respective function of the ACL and the ALS could differ under higher torque up to 10 Nm. Disarticulation of the hip may impair the stabilizing function of the iliotibial band on knee rotational stability, even though it was left intact from its proximal insertion to the Gerdy tubercle. Our study suffered the drawbacks associated with work on elderly specimens. Woo et al.⁴⁹ found that ultimate load and stiffness reduced with age. Given that younger patients would have stronger ACL, the small laxity increase found in the study would have been even smaller and more difficult to detect. A possible foot and ankle movement under the boot strap cannot be totally excluded during the internal rotation. A difference between an external device like the Rotameter compared with invasive methods as navigation system was seen in a previous study.²⁹ However, as the possible measurement error in the present study was constant, it does not change the measurement of differences between the intact knees and the transected knees. There is a need for further biomechanical studies to better define the respective function of the ALS and the ALL in providing anterolateral knee stability at greater degrees of flexion of the knee.

Conclusions

In a pure rotational cadaveric test model, the ACL and the ALS contribute to resistance to passive IR of the knee.

Acknowledgment

The authors thank Mr. Eric Berton for his help in the preparation of the cadaveric specimens and Steve

Batchelor for his help in the translation of the manuscript.

References

1. Muller W. *The knee: Form, function and ligament reconstruction*. New York, NY: Springer Verlag, 1983;40-43.
2. Fu FH, van Eck CF, Tashman S, Irrgang JJ, Moreland MS. Anatomic anterior cruciate ligament reconstruction: A changing paradigm. *Knee Surg Sports Traumatol Arthrosc* 2015;23:640-648.
3. Yasuda K, Kondo E, Ichiyama H, et al. Anatomic reconstruction of the anteromedial and posterolateral bundles of the anterior cruciate ligament using hamstring tendon grafts. *Arthroscopy* 2004;20:1015-1025.
4. Lie DTT, Bull AMJ, Amis AA. Persistence of the mini pivot shift after anatomically placed anterior cruciate ligament reconstruction. *Clin Orthop* 2007;457:203-209.
5. Biau DJ, Tournoux C, Katsahian S, Schranz P, Nizard R. ACL reconstruction: A meta-analysis of functional scores. *Clin Orthop* 2007;458:180-187.
6. Chouliaras V, Ristanis S, Moraiti C, Stergiou N, Georgoulis AD. Effectiveness of reconstruction of the anterior cruciate ligament with quadrupled hamstrings and bone-patellar tendon-bone autografts: An in vivo study comparing tibial internal-external rotation. *Am J Sports Med* 2007;35:189-196.
7. Ferretti A, Monaco E, Vadala A. Rotatory instability of the knee after ACL tear and reconstruction. *J Orthop Traumatol* 2014;15:75-79.
8. Hussein M, van Eck CF, Cretnik A, Dinevski D, Fu FH. Individualized anterior cruciate ligament surgery: A prospective study comparing anatomic single- and double-bundle reconstruction. *Am J Sports Med* 2012;40:1781-1788.
9. Meredith RB, Vance KJ, Appleby D, Lubowitz JH. Outcome of single-bundle versus double-bundle reconstruction of the anterior cruciate ligament: A meta-analysis. *Am J Sports Med* 2008;36:1414-1421.
10. Lubowitz JH, Provencher MT, Brand JC, Rossi MJ. The knee anterolateral ligament. *Arthroscopy* 2014;30:1385-1388.
11. Lemaire M. Ruptures anciennes du ligament croisé antérieur du genou. *J Chir* 1967;93:311-320.
12. Ireland J, Trickey EL. Macintosh tenodesis for anterolateral instability of the knee. *J Bone Joint Surg Br* 1980;62:340-345.
13. Dodds AL, Gupte CM, Neyret P, Williams AM, Amis AA. Extra-articular techniques in ACL reconstruction: A literature review. *J Bone Joint Surg Br* 2011;93:1140-1148.
14. Pomajzl R, Maerz T, Shams C, Guettler J, Bicos J. A review of the anterolateral ligament of the knee: Current knowledge regarding its incidence, anatomy, biomechanics, and surgical dissection. *Arthroscopy* 2015;31:583-591.
15. Hughston JC, Andrews JR, Cross MJ, Moschi A. Classification of knee ligament instabilities. Part II. The lateral compartment. *J Bone Joint Surg Am* 1976;58:173-179.

16. George MS, Dunn WR, Spindler KP. Current concepts review: Revision anterior cruciate ligament reconstruction. *Am J Sports Med* 2006;34:2026-2037.
17. Segond P. *Recherches cliniques et expérimentales sur les épanchements sanguins du genou par entorse*. Paris, France: Aux Bureaux du Progrès Médical; 1879. <http://gallica.bnf.fr/ark:/12148/bpt6k5712206r>. Accessed September 20, 2015.
18. Vieira EL, Vieira EA, da Silva RT, Berlfein PA, Abdalla RJ, Cohen M. An anatomic study of the iliotibial tract. *Arthroscopy* 2007;23:269-274.
19. Claes S, Vereecke E, Maes M, Victor J, Verdonk P, Bellemans J. Anatomy of the anterolateral ligament of the knee. *J Anat* 2013;223:321-328.
20. Vincent J-P, Magnussen RA, Gezmez F, et al. The anterolateral ligament of the human knee: An anatomic and histologic study. *Knee Surg Sports Traumatol Arthrosc* 2012;20:147-152.
21. Dodds AL, Halewood C, Gupte CM, Williams A, Amis AA. The anterolateral ligament: Anatomy, length changes and association with the Segond fracture. *Bone Joint J* 2014;96-B:325-331.
22. Helito CP, Demange MK, Bonadio MB, et al. Radiographic landmarks for locating the femoral origin and tibial insertion of the knee anterolateral ligament. *Am J Sports Med* 2014;42:2356-2362.
23. Lutz C, Sonnery-Cottet B, Niglis L, Freychet B, Clavert P, Imbert P. Behavior of the anterolateral structures of the knee during internal rotation. *Orthop Traumatol Surg Res* 2015;101:523-528.
24. Van der Watt L, Khan M, Rothrauff BB, et al. The structure and function of the anterolateral ligament of the knee: a systematic review. *Arthroscopy* 2015;31:569-582.e3.
25. Dombrowski ME, Costello JM, Ohashi B, et al. Macroscopic anatomical, histological and magnetic resonance imaging correlation of the lateral capsule of the knee. *Knee Surg Sports Traumatol Arthrosc* February 4, 2015 [Epub ahead of print].
26. Parsons EM, Gee AO, Spiekerman C, Cavanagh PR. The biomechanical function of the anterolateral ligament of the knee. *Am J Sports Med* 2015;43:669-674.
27. Spencer L, Burkhart TA, Tran MN, et al. Biomechanical analysis of simulated clinical testing and reconstruction of the anterolateral ligament of the knee. *Am J Sports Med* 2015;43:2189-2197.
28. Monaco E, Ferretti A, Labianca L, et al. Navigated knee kinematics after cutting of the ACL and its secondary restraint. *Knee Surg Sports Traumatol Arthrosc* 2012;20:870-877.
29. Lorbach O, Wilmes P, Theisen D, et al. Reliability testing of a new device to measure tibial rotation. *Knee Surg Sports Traumatol Arthrosc* 2009;17:920-926.
30. Lorbach O, Pape D, Maas S, et al. Influence of the anteromedial and posterolateral bundles of the anterior cruciate ligament on external and internal tibiofemoral rotation. *Am J Sports Med* 2010;38:721-727.
31. Mouton C, Seil R, Agostinis H, Maas S, Theisen D. Influence of individual characteristics on static rotational knee laxity using the Rotameter. *Knee Surg Sports Traumatol Arthrosc* 2012;20:645-651.
32. Noyes FR, Jetter AW, Grood ES, Harms SP, Gardner EJ, Levy MS. Anterior cruciate ligament function in providing rotational stability assessed by medial and lateral tibiofemoral compartment translations and subluxations. *Am J Sports Med* 2015;43:683-692.
33. Kondo E, Merican AM, Yasuda K, Amis AA. Biomechanical analysis of knee laxity with isolated anteromedial or posterolateral bundle-deficient anterior cruciate ligament. *Arthroscopy* 2014;30:335-343.
34. Kanamori A, Woo SL, Ma CB, et al. The forces in the anterior cruciate ligament and knee kinematics during a simulated pivot shift test: A human cadaveric study using robotic technology. *Arthroscopy* 2000;16:633-639.
35. Diermann N, Schumacher T, Schanz S, Raschke MJ, Petersen W, Zantop T. Rotational instability of the knee: Internal tibial rotation under a simulated pivot shift test. *Arch Orthop Trauma Surg* 2009;129:353-358.
36. Markolf KL, Park S, Jackson SR, McAllister DR. Anterior-posterior and rotatory stability of single and double-bundle anterior cruciate ligament reconstructions. *J Bone Joint Surg Am* 2009;91:107-118.
37. Welsh RP. Knee joint structure and function. *Clin Orthop* 1980;147:7-14.
38. Arnoczky SP. Anatomy of the anterior cruciate ligament. *Clin Orthop* 1983;172:19-25.
39. Smigielski R, Zdanowicz U, Drwięga M, Ciszek B, Ciszowska-Łyson B, Siebold R. Ribbon like appearance of the midsubstance fibres of the anterior cruciate ligament close to its femoral insertion site: A cadaveric study including 111 knees. *Knee Surg Sports Traumatol Arthrosc* 2015;23:3143-3150.
40. Caterine S, Litchfield R, Johnson M, Chronik B, Getgood A. A cadaveric study of the anterolateral ligament: Re-introducing the lateral capsular ligament. *Knee Surg Sports Traumatol Arthrosc* 2015;23:3186-3195.
41. Lane CG, Warren R, Pearle AD. The pivot shift. *J Am Acad Orthop Surg* 2008;16:679-688.
42. Engebretsen L, Lew WD, Lewis JL, Hunter RE. The effect of an iliotibial tenodesis on intraarticular graft forces and knee joint motion. *Am J Sports Med* 1990;18:169-176.
43. Noyes FR, Barber SD. The effect of an extra-articular procedure on allograft reconstructions for chronic ruptures of the anterior cruciate ligament. *J Bone Joint Surg Am* 1991;73:882-892.
44. Sonnery-Cottet B, Thauinat M, Freychet B, Pupim BHB, Murphy CG, Claes S. Outcome of a combined anterior cruciate ligament and anterolateral ligament reconstruction technique with a minimum 2-year follow-up. *Am J Sports Med* 2015;43:1598-1605.
45. Imbert P. Minimally invasive extra-articular anterolateral reinforcement: A new technique. *Arthroscopy* 2007;23:907.e1-907.e4.
46. Hewison CE, Tran MN, Kaniki N, Remtulla A, Bryant D, Getgood AM. Lateral extra-articular tenodesis reduces rotational laxity when combined with anterior cruciate ligament reconstruction: A systematic review of the literature. *Arthroscopy* 2015;31:2022-2234.
47. Dejour D, Zaffagnini S, Ntagiopoulos PG, Grassi A, Marcheggiani Muccioli GM, Maurilio Marcacci M. ACL reconstruction with extra-articular plasty. In: Siebold R,

- Dejour D, Zagfanini S, eds. *ACL reconstruction*. New York: Springer, 2014;299-316.
48. Hoshino Y, Araujo P, Ahldén M, et al. Quantitative evaluation of the pivot shift by image analysis using the iPad. *Knee Surg Sports Traumatol Arthrosc* 2013;21: 975-980.
49. Woo SL-Y, Kanamori A, Zeminski J, Yagi M, Papageorgiou C, Fu FH. The effectiveness of reconstruction of the anterior cruciate ligament with hamstrings and patellar tendon. A cadaveric study comparing anterior tibial and rotational loads. *J Bone Joint Surg Am* 2002;84: 907-914.

Should you Review for *Arthroscopy*?

You Can Earn CME Credits in the Process!

Be part of our peer-review process. It's rewarding, enlightening, and a great service to your profession. It's also an important commitment of time and effort.

Do you have what it takes to volunteer? If so, you really should.

Visit <http://ees.elsevier.com/arth/> and click on the links found in the Reviewer Information box.